



PATIENT

Luna Smith

SPECIES

Canine

BREED

Cocker Spaniel

SEX

Female Spayed

AGE

10 years

WEIGHT

27.1lbs

INTERPRETED BY

Maggie Machen Lamy,
DVM, DACVIM
(Cardiology)

IMAGING PERFORMED BY

A. Nicastro, DVM

HOSPITAL NAME

Waterway Animal
Hospital

REFERRING VET

Dr. Roland

INVOICE

47481

DATE

/26

PRESENTING CLINICAL SIGNS

History: Grade 3/6 heart murmur.

ECHOCARDIOGRAM FINDINGS

2D, m-mode, color flow and doppler imaging is available. The mitral valve leaflets are thickened with no obvious prolapse into the left atrial lumen. Trace mitral regurgitation. Normal velocity. Normal left atrial dimension. Normal LV diameter with normal myocardial function. The LV wall thickness is normal. The tricuspid valve appears normal with trace tricuspid regurgitation. Elevated TR velocity. Mild right atrial dilation. Moderate right ventricular hypertrophy and remodeling indicative of pressure overload. No significant right ventricular dilation. Severe elevation of pulmonic outflow velocities at the level of the valve. The PV leaflets are thickened and tethered, consistent with congenital stenosis. Moderate post-stenotic dilation of the main pulmonary artery. Moderate pulmonic insufficiency. The aortic valve appears to have normal morphology and mobility. No AI. No obvious cardiac shunts are visualized. No pericardial or pleural effusion noted.

CARDIAC CHART

CANINE CARDIAC PARAMETERS	MR VMAX (m/s)	TR VMAX (m/s)	LA/AO (Boon method)	LA/AO (Heart Base; Swe)	FS (%)	EF (%)	EPSS (cm)
NORMAL PARAMETER	4.5-5.5	<2.7	1.3	<1.6	28-40	40-100	<0.6
PATIENT	5.2	4.0	NM	1.35	28	50	NM
CANINE CARDIAC PARAMETERS	HR (BPM)	AV VMAX (m/s)	PV MAX (m/s)	BODY WEIGHT (kg)	LA 2D short axis Base view (cm)	LVIDd Avg; 2D and m-mode short axis (cm)	LVIDs Avg; 2D and m-mode short axis (cm)
NORMAL PARAMETER	50-100	0.7-1.7	0.7-1.6	BELOW	BELOW	BELOW	BELOW
PATIENT	NM	1.9	5.2	12.3	2.2	2.6	1.9
*Normal chamber parameters expressed as a mean value (SD)				3	1.27 (5.3)	2.46 (2.46)	1.36 (5.5)
BODY WEIGHT DEPENDENT PARAMETERS				5	1.40 (4.5)	2.74 (5.2)	1.60 (4.7)
<i>*Note: All measurements based upon multi-modal images and methods. An average value is reported.</i>				10	1.50 (3.8)	3.27 (3.5)	2.06 (3.1)
				15	1.83 (2.0)	3.71 (2.4)	2.43 (2.1)
				20	2.02 (1.9)	4.14 (2.2)	2.80 (2.0)
				25	2.18 (2.4)	4.48 (2.9)	3.10 (2.5)
				30	2.33 (3.3)	4.83 (3.9)	3.39 (3.4)
				35	2.48 (4.3)	5.17 (5.0)	3.69 (4.5)
				40	2.62 (5.2)	5.48 (6.1)	3.96 (5.4)
				50	2.88 (7.1)	6.07 (8.3)	4.46 (7.4)

INTERPRETATION OF THE FINDINGS & FURTHER RECOMMENDATIONS

The cause of the murmur is elevated flow velocity through the pulmonary artery consistent with severe pulmonic stenosis. No sub or supra valvular components were identified at this time, making a purely valvular stenosis most likely. The degree of obstruction is severe based upon the maximum velocity/pressure gradient across the pulmonic valve with secondary hypertrophy and



PATIENT

Luna Smith

SPECIES

Canine

BREED

Cocker Spaniel

SEX

Female Spayed

AGE

10 years

WEIGHT

27.1lbs

INTERPRETED BY

Maggie Machen Lamy,
DVM, DACVIM
(Cardiology)

IMAGING PERFORMED BY

A. Nicastro, DVM

HOSPITAL NAME

Waterway Animal Hospital

REFERRING VET

Dr. Roland

INVOICE

47481

DATE

/26

remodeling of the right ventricle. Trace mitral and tricuspid regurgitation are also noted, which may reflect early valve disease. Follow up is advised. No additional issues are identified.

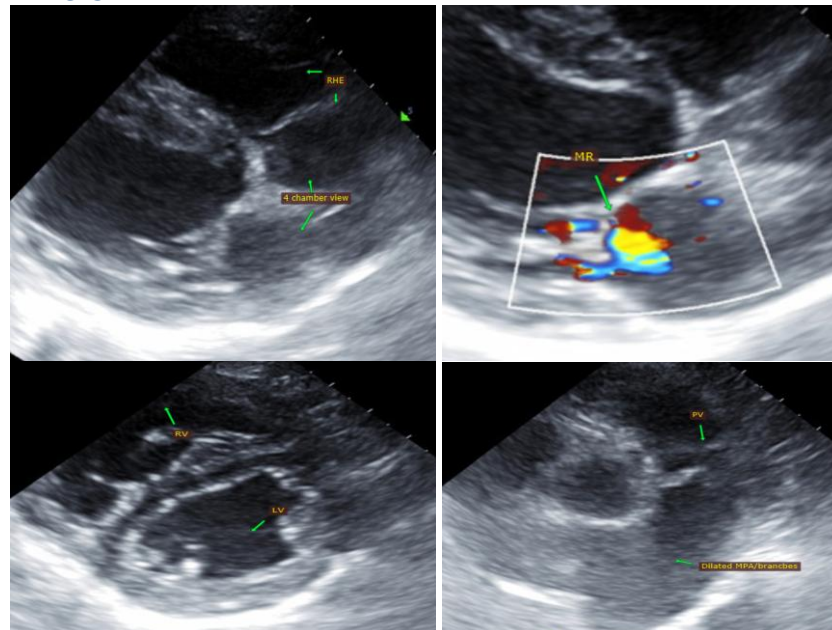
While severe PS is typically a limiting disease, the finding of only mild heart enlargement in a senior dog, this is certainly a good sign. At this time point it is unlikely that the patient will experience right-sided CHF, although not entirely ruled out. In an asymptomatic dog, even with significant stenosis seen here, there is no obvious indication for Atenolol therapy at this time. If the patient experiences any exercise intolerance or syncope, this can be revisited.

Monitor for development of associated clinical signs (collapse, abdominal distention, cough, labored breathing). Mild exercise restriction is advised. Omega fatty acid supplementation may have some long-term benefit, given these cases are predisposed to development of arrhythmias going forward.

Anesthetic risk is mild to moderate at this time. **Avoid heart rate stimulating drugs such as atropine or glycopyrrolate unless absolutely necessary.** Avoid vasodilators such as acepromazine. Mild IV fluid restriction is advised. Cardiac protective drug choices (opioid/benzodiazepine premedication, propofol or alfaxalone induction, isoflurane gas) are recommended. Pre-oxygenate for 5-10 minutes prior to induction and recover in O2 if possible. Monitor for arrhythmias, hypotension, and hypoxia both intra and post-operatively and intervene as necessary.

Recommend recheck echocardiogram annually to screen for concurrent disease, sooner if clinical signs arise.

IMAGES





PATIENT

Luna Smith

SPECIES

Canine

BREED

Cocker Spaniel

SEX

Female Spayed

AGE

10 years

WEIGHT

27.1lbs

INTERPRETED BY

Maggie Machen Lamy,
DVM, DACVIM
(Cardiology)

**IMAGING
PERFORMED BY**

A. Nicastro, DVM

HOSPITAL NAME

Waterway Animal
Hospital

REFERRING VET

Dr. Roland

INVOICE

47481

DATE

/26

The information and recommendations provided are based on the images presented by the referring veterinarian. No evaluation can be communicated regarding pathology that was not visible in the image/video clips provided.

Thank you for this referral. This report was generated using transcription software, and minor dictation errors may be present. If the clinical or image interpretation does not parallel your findings or if I can be of any further assistance, please contact me.

Maggie Machen Lamy, DVM
Diplomate of the American College of Veterinary Internal Medicine (Cardiology)
info@sonopath.com